Esthetic consideration in complete denture

Esthetics: the branch of philosophy dealing with beauty; in dentistry, the theory and philosophy that deal with beauty and the beautiful, especially with respect to the appearance of a dental restoration, as achieved through its form and/or color; those subjective and objective elements and principles underlying the beauty and attractiveness of an object, design, or principle(GPT9).

Esthetic dentistry: is a combination between the 'art and science of dentistry'. The simultaneous application of technical and artistic skills enables a practitioner to achieve outstanding esthetic and functional results.

STEPS FOR ACHIEVING COMPLETE DENTURE ESTHETICS:

1. *Accurate impressions*
2. *Jaw relation*
3. *Selection of anterior teeth*
4. *Arrangement with esthetic consideration.*
5. *Characterization of denture teeth.*

1. ACCURATE IMPRESSIONS:

Dentures defines the appearance of the lower one-third of the face in edentulous patients. As teeth are lost, functions of facial muscles are impaired. Resultant edentulous appearance has profound influence on patient. The lips must be supported correctly if normal tone of the orbicularis oris muscle is to be re-established. Insufficient or unnecessary support of the lips effect the philtrum, nasolabial, and mentolabial folds,

Dr. Wasmaa Sadik

altering natural lip contours. Supporting the facial musculature with properly formed denture borders is necessary. Thickness of labial flange of both dentures is accomplished at the impression phase of treatment, so that the esthetics as well as retention and stability are important goals. Overextension of these borders gives the patient the appearance of having a cotton roll under the lip. A long-standing edentulous patient requires thicker borders.

(Fig. 1 shows patient before and after wearing denture)

2. JAW RELATION:

Correct vertical dimension is essential for proper positioning of Orbicularis oris and associated muscles. establish or re-establish the correct vertical dimension of occlusion to reestablish physiologic muscle length and eliminate a prognathic looks. Insufficient vertical dimension at occlusion or excessive vertical dimension of occlusion will have a negative effect on patient's esthetics.

(Fig2 (A) shows patient with decrease vertical dimension (B) the lady has increase vertical dimension).

Dr. Wasma

3. Selection of anterior teeth:

The selection of teeth and their arrangement to meet esthetic requirements demands artistic skill in addition to scientific knowledge. But there are anatomic landmarks manufactured aids that can be used as guides. Best method to develop the skill is to observe natural teeth.

The objective of anterior tooth arrangement is:

1. Esthetics.
2. Proper lip support.
3. phonetics
4. function

Some of the factors influencing the size and form of the anterior teeth are

(1) the size of the face; (2) the amount of available interarch space; (3) the measured distance between the distal of the right and left maxillary canines, using the arch and incisal papilla as measuring guides; (4) the length of the Lips; and (5) the size and relation of the arches.

5. Arrangement with esthetic consideration:

It is the modification of the form and color of the denture base and teeth to produce a more lifelike/natural appearance.

The arrangement is influenced by:

(1) age.
(2) gender.
(3) personality.
(4) cosmetic factor.
(5) artistic reflection.

(1) Age:

a) The interincisal distance increases with age; therefore. the mandibular teeth become more visible.

Dr. Wasmaa Sadik

b) Teeth abrade with age. The central and lateral incisors abrade in a straight line, the canines abrade in a curve the abrasion of the incisal edges of the anterior teeth flattens the arch.

c) Gingival tissues recede with age as in (fig.4). This recession can be reproduced by selecting a long tooth, contouring the wax.

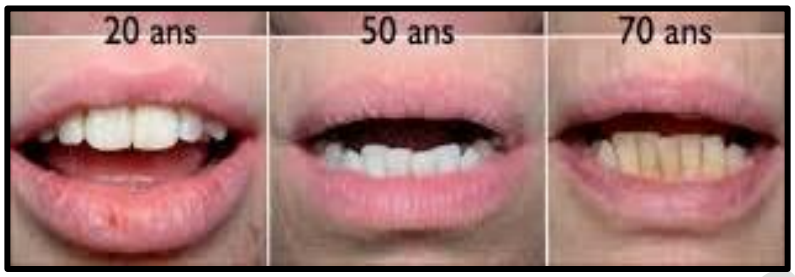

(fig.3 old patient shows the lower anterior teeth

(fig.4 shows patient with gingival recession)

(2) Gender:

a) Roundness of the arch form denotes femininity, and squareness denotes masculinity.

b) Viewed from in front, the distal surfaces of the central incisors of females are usually rotated in a posterior direction which is not present in male.

c) In the arrangement for females, the mesial surface of the lateral incisor is often seen in an anterior relation to the distolabial surface of the central incisor as seen in (fig. 5) The distal surface of the lateral incisor is rotated in a posterior direction. The smile is softened as a result of this arrangement. For the male, the mesial

(fig.5)

Dr. Wasmaa Sadik

surface of the lateral incisor is often hidden behind the distal surface of the central incisor.

d) The distal surfaces of the canines for females are rotated in a posterior direction; whereas the canines for males are rotated less in a posterior direction as in (fig. 5).

(3) Personality:

The people's personality can be influenced by the appearance of their teeth It is the obligation of the dentist to arrange the artificial teeth in a manner to encourage the development of an attractive personality.

(4) Artistic *Reflection:*

Artistic reflection is the arrangement of the teeth to reflect the dentist's concept of what appears natural for the patient.

The artistic ability of the dentist is often taxed to achieve a composition of teeth that harmonizes with the surrounding features and is acceptable to the patient.

Characterization of teeth:

1. creating asymmetry in the divergencies of the proximal surfaces of the teeth from the contact points.
2. varying the direction of the long axis.
3. Use an eccentric midline.
4. Diastema
5. grinding the incisal edges of lower anterior teeth.
6. Create a good smile line by the proper placing of the maxillary posterior teeth mediolaterally in relation to the cheek. When the teeth are placed too far laterally, the buccal corridor is eliminated, resulting in a harsh, ugly, and toothy appearance as shown in (fig. 7&8).

Dr. Wasmaa Sadik

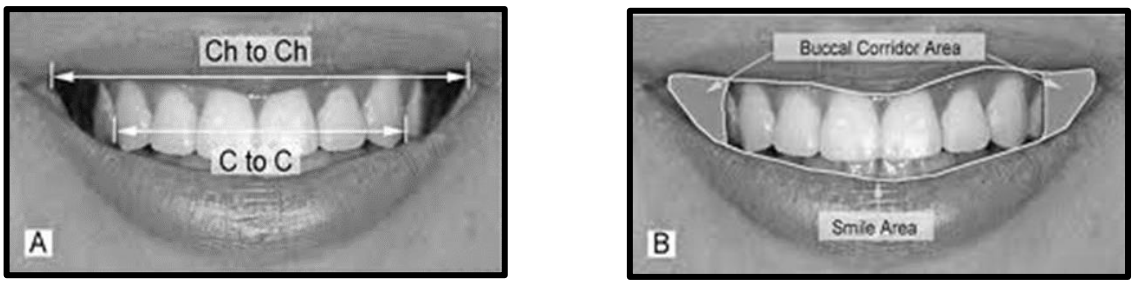

(fig. 7) the pictures show the buccal corridor.

Buccal corridor -it is the space between the buccal surface of posterior teeth and the inner surface of the cheek. The buccolingual position of occlusal rim should permit a good position of buccal corridor. The excessive space result when the posterior part of the rim is positioned too far lingually

(fig. 8) Influence of buccal corridor dimension on smile esthetics

- The smile line is formed by the bottom edge of the upper teeth. Ideally this line should follow the curvature of the lower lip.
- A straight flat smile line is less pleasing.

A reverse curve where the front teeth appear to be shorter than the canines gives a look of aging and wear and can be quite unattractive as seen in (fig. 9).

Dr. Wasma Sadik

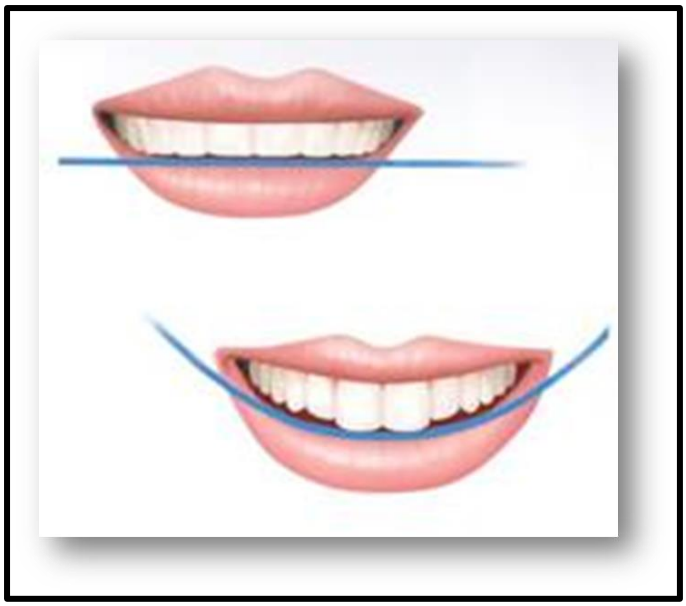

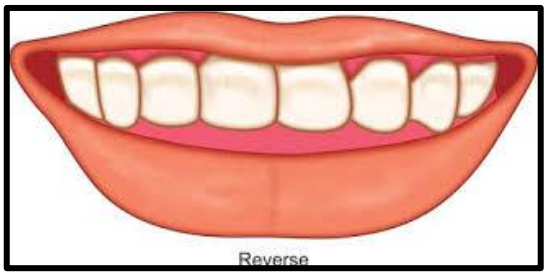

(fig.9) type of smile line.

References:

1. Text book of complete denture, O. Rahn, M. Heartwell, London.
2. Kh. Monalee Devi, Sanjna Nayar" Esthetics In Compelete Denture – A Review", Journal of Dental and Medical Sciences 2018.

Dr. Wasmaa Sadik